



OFFICE OF THE DISTRICT MEDICAL EXAMINER  
DISTRICT 15 – STATE OF FLORIDA  
PALM BEACH COUNTY  
3126 GUN CLUB ROAD  
WEST PALM BEACH, FLORIDA 33406-3005  
(561) 688-4575  
(561) 688-4592 FAX

**NAME:** BERNSTEIN, SIMON

**CASE NUMBER:** 12-0913

**DATE OF DEATH:** September 13, 2012

**AGE:** 76

**SEX:** M

**RACE:** W

**DATE OF AUTOPSY:** September 14, 2012 / 11:00 a.m.

---

---

**AUTOPSY FINDINGS:**

1. Acute subendocardial myocardial infarct.
2. Status post coronary artery bypass grafting, remote.
3. Severe calcific coronary atherosclerosis.
4. Focal myocardial fibrosis.
5. Bronchopneumonia.
6. Severe aortic atherosclerosis.
7. Fibrous pericarditis.
8. Calcific aortic valve annulus.
9. Nephrosclerosis.
10. Cirrhosis with chronic hepatitis.
11. Old splenic infarct.
12. Pleural effusions.
13. Sternum fracture.
14. Anterior rib fractures.
15. Osteoporosis.
16. Status post appendectomy, remote.
17. Status post cholecystectomy, remote.

**NAME:** BERNSTEIN, SIMON

**CASE NUMBER:** 12-0913

**CAUSE OF DEATH:** Myocardial infarct due to severe coronary atherosclerosis

**CONTRIBUTORY CAUSE OF DEATH:** Bronchopneumonia, cirrhosis

**MANNER OF DEATH:** Natural

**OPINION:** Simon Bernstein, a 76-year-old man, died from a heart attack due to blockage of the arteries that feed his heart. He also had pneumonia and cirrhosis. His blood hydrocodone concentration was therapeutic. There was no overdose. He did not have meningitis.



Michael D. Bell, M.D.  
District Medical Examiner

Date Signed: November 8, 2012

MDB:df

**NAME:** BERNSTEIN, SIMON

**CASE NUMBER:** 12-0913

**EXTERNAL EXAMINATION:**

The body is that of a 5 foot 7 inch, 191 pound, overweight, white man who appears the reported age of 76 years. His body mass index is 29.9.

The body is well preserved and cold. Mild rigor mortis is detected in the extremities. Purple livor mortis is on his back.

The decedent is normocephalic without apparent injury to the face or scalp. The decedent has short, gray-brown hair. He has brown irides with no conjunctival petechiae. There is slight chemosis. The corneas are clear. The sclerae are nonicteric. No facial, nasal or mandibular fractures are palpated. The nasal septum is intact. No froth or fluid escapes from the nose or mouth. The teeth are natural and in good repair. There is no trauma of the lips, gums or frenulum.

The neck is symmetrical and has no trauma or injury. There is no palpable crepitus or hypermobility. No neck masses are observed.

The thorax is symmetric. The abdomen is protuberant with small ecchymoses on the abdomen. The external genitalia and anus are unremarkable. The decedent is circumcised.

The arms are symmetrical and normally developed. The arms have no needle tracks. The fingernails are short. The legs are symmetrical, and there is slight pedal edema. The back shows a symmetrical external contour and the spine is straight. The back has no trauma. The skin shows no rashes.

**IDENTIFICATION:**

No tattoos are on the body. A vertical 9 inch scar is in the midline of the chest. A vertical 10 inch scar is on the right abdomen. A transverse 3 inch scar is in the left groin. Three vertical scars run along the inside of the left leg, and they are 3 inches, 4 inches, and 18 inches, respectively.

The decedent is unclothed.

**EVIDENCE OF MEDICAL INTERVENTION:**

Two hospital blood tubes accompany the body, and they are dated 9/12/2012. The decedent has multiple needle punctures on the right and left antecubital fossa, lower arms and right hand, and all of them are surrounded by small ecchymoses. An identification band is on his right wrist.

**NAME:** BERNSTEIN, SIMON

**CASE NUMBER:** 12-0913

**INTERNAL EXAMINATION:**

**BODY CAVITIES:**

The sternum is fractured. Anterior ribs 2 through 6 are fractured bilaterally. There is a small amount of extravasated blood surrounding the fracture sites. There is extravasated blood in the anterior mediastinal soft tissues. The bones are osteoporotic, and the soft tissue is friable. There are no fractures of the clavicles, vertebral column or pelvis. The right and left pleural cavities each contain an estimated 200 to 300 milliliters of clear, straw-colored fluid. There is no blood within the peritoneal cavity. The pericardial cavity is obliterated by fibrous adhesions. The pericardial sac and diaphragm are intact. There are no fibrous or fibrinous adhesions involving the intestines. No aromatic or unusual odors are detected inside the body. The intravascular blood is liquid and clotted.

**HEAD AND CENTRAL NERVOUS SYSTEM:**

The scalp has no edema. The subgaleal tissues have no contusions or injuries. The temporal muscles have no contusions. The skull is intact and has no fractures. No epidural or subdural hematomas are present. The dura mater is intact and has no discoloration.

The 1400 gram brain has thin, transparent leptomeninges with no subarachnoid blood or exudate seen. The leptomeninges are not congested or hyperemic. The cerebral and cerebellar gyri and sulci are of normal size and configuration and have no edema or swelling. No cingulate, uncinata or cerebellar tonsil herniation is present. No contusions or defects are on the surface of the brain. The olfactory bulbs and rest of the cranial nerves are intact. The vertebral, basilar and cerebral arteries, including the arterial circle of Willis, have a moderate amount of atherosclerosis.

The cerebral hemispheres have a thin, gray, cortical ribbon with no slit-like or punctate hemorrhages. The subjacent white matter, including the centrum ovale and corpus callosum, has no discoloration, hematomas or masses. The lateral ventricles are enlarged but have normal configuration and contain no blood. The third ventricle is enlarged. The caudate and lenticular nuclei are unremarkable, as is the thalamus. The mammillary bodies have no discoloration or hemorrhage. The hippocampal gyri are symmetric and have no sclerosis. The occipital lobes are normal. The midbrain, pons and medulla oblongata are unremarkable. The folia cerebelli are neither atrophic nor swollen. The cerebellar white matter and deep midline nuclei are normal. The fourth ventricle and cerebral aqueduct are of normal size and contain no tumor, blood or exudate.

**NECK:**

The oropharynx is light red-yellow with no trauma or injuries. The epiglottis is light red-yellow and leaf-like, and there is a small amount of aryepiglottic edema. No food or foreign objects obstruct the oropharynx, larynx, trachea or bronchi. The hyoid bone and thyroid cartilages are intact. The anterior cervical neck strap muscles and soft tissues have no contusions or injuries. The prevertebral muscles, fascia and soft tissues have no contusions. The anterior cervical vertebral column is intact. The thyroid gland has its normal anatomic size and location. The thyroid gland is slightly nodular. The cervical lymph nodes are not enlarged.

**NAME:** BERNSTEIN, SIMON

**CASE NUMBER:** 12-0913

**CARDIOVASCULAR:**

The 650 gram heart is covered by easily broken fibrous adhesions. No petechiae or contusions are on the epicardial surface. There is an increased amount of epicardial fat. The heart is right coronary artery dominant. The native coronary arteries arise normally from the aortic root, and their ostia are patent. The native coronary arteries have severe calcific coronary atherosclerosis. A stent is in the native right coronary artery. A clot is in this stent. The native left anterior descending coronary artery has 90-95% intraluminal narrowing by atherosclerosis. The native left circumflex coronary artery has 95% intraluminal narrowing by atherosclerosis. A left thoracic artery graft inserts in the left anterior descending coronary artery. This graft is patent. Two saphenous vein grafts arise from the ascending aorta. One inserts into the posterior descending coronary artery and the other into the left marginal coronary artery. The former saphenous vein graft is occluded at its ostium. The saphenous vein graft to the left marginal coronary artery is narrowed to a pinpoint at its ostium. A stent is in the proximal graft and beyond the stent distally the lumen is narrowed to a pinpoint again.

The free left ventricular wall, ventricular septum, and right ventricular wall are 1.8, 2.0, and 0.3 centimeters thick, respectively. The atria and right ventricles are dilated. The left ventricle chamber is 4 centimeters in diameter. The myocardium is red-brown and firm, with focal scarring in the posterior and lateral left ventricle walls. The scars are up to 1 centimeter in greatest dimension. The endocardium is smooth and transparent with a 1 centimeter area of endocardial thickening in the right ventricle. There is no endocardial hemorrhage or mural thrombosis.

The tricuspid, pulmonic, mitral and aortic valve circumferences are 12.9, 9.0, 11.0, and 7.0 centimeters, respectively. The valves have no ballooning, deformities or vegetations. The commissures are normal. The chordae tendineae are neither ruptured nor thickened. There is moderate calcification of the aortic valve annulus. The rest of the valves and annuli have no calcification.

The aorta has no trauma or injuries. The aorta has severe calcific and ulcerative atherosclerosis. There is no aortic dissection or aneurysm formation.

**RESPIRATORY:**

The right and left lungs weigh 1180 and 910 grams, respectively. The lungs are normally inflated and occupy most of the pleural cavities. Both lungs have smooth, glistening, transparent pleural surfaces, except for fibrous adhesions involving the posterior lateral left upper lobe. No anthracotic pigment is on the pleural surfaces. No depressions, nodules or bullae are seen. The lungs are light brown anteriorly and dark red posteriorly. The parenchyma has focal nodular areas of consolidation in the posterior segments of the lower lobes. The parenchyma exudes red fluid. No tumor, abscesses, granulomas or pulmonary thromboemboli are seen. The bronchial tree contains red fluid. The pulmonary arteries are normal. The hilar lymph nodes are normal.

**NAME:** BERNSTEIN, SIMON

**CASE NUMBER:** 12-0913

**HEPATOBIILIARY SYSTEM:**

The 1990 gram liver has an intact nodular capsule, and its normal parenchyma is replaced by 2 to 4 millimeter in diameter brown, cirrhotic nodules. No infarcts, granulomas or tumors are seen. The gallbladder is surgically absent.

**HEMOLYMPHATIC SYSTEM:**

The 340 gram spleen has a smooth, intact capsule with no trauma or injury. A 4 x 1 centimeter shrunken, yellow infarct is present. No granulomas or tumors are seen within the otherwise red-purple, firm parenchyma. Gray-white follicles are not identified.

**ENDOCRINE SYSTEM:**

The pancreas is pale brown, lobular and soft with no fat necrosis, extravasated blood, tumor or fibrosis. The adrenal glands are thin and have yellow cortices and gray-white medullae. No hemorrhage or tumor is seen in the adrenal glands.

**GASTROINTESTINAL SYSTEM:**

The esophagus is lined by a smooth, gray-white mucosa with no ulcers, tumors or esophageal varices. The stomach is intact and contains 150 milliliters of red fluid. No aromatic or unusual odors are detected. No pills, capsules or granular material are seen. No blood is in the stomach. The gastric mucosa is red-brown with normal rugae and no ulcers, polyps or tumors. The duodenum has no ulcers. The small and large bowel has no perforation, obstruction or infarction. No mass or tumor is seen in the gastrointestinal tract. The appendix is not identified.

**UROGENITAL SYSTEM:**

The right and left kidneys weigh 200 and 190 grams, respectively. Both kidneys are enlarged and have scarred, pitted and granular, red-brown surfaces. There is no trauma or injury to the kidneys. The cortices are reduced in thickness to 4 millimeters, and there is an indistinct corticomedullary junction. There are no infarcts, granulomas or tumor. There is no hydronephrosis or renal calculi. There is an increased amount of peripelvic fat. The ureters and bladder are normal. The bladder is intact but contains no urine.

**NAME:** BERNSTEIN, SIMON

**CASE NUMBER:** 12-0913

**DATE:** October 18, 2012

**NUMBER OF SLIDES:** 8

**MICROSCOPIC EXAMINATION**

**HEART:** Myocyte disarray and focal myocardial fibrosis. Myocyte hypertrophy. Acute subendocardial infarction with scant neutrophil infiltration.

**LEFT CORONARY ARTERY:** 90-95% intraluminal narrowing by atherosclerosis.

**LEFT ANTERIOR DESCENDING CORONARY ARTERY:** 90-95% intraluminal narrowing by atherosclerosis.

**LUNGS:** Bronchopneumonia. Rare fat emboli in pulmonary arteries.

**LIVER:** Cirrhosis with chronic hepatitis.

**KIDNEY:** Arteriosclerosis.

**SPLEEN:** Old infarct.

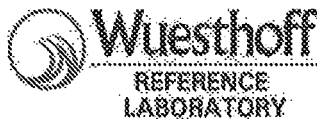**LYMPH NODE:** Unremarkable.



Michael D. Bell, M.D.  
District Medical Examiner

Date Signed: 10/29/12

MDB:df



# Wuesthoff Reference Laboratory

6800 Spyglass Court  
Melbourne, Florida 32940  
Julie Bell, M.D., Laboratory Director

Patient: **BERNSTEIN, SIMON**  
Client Patient ID: **15-12-913**  
Physician: **BELL, MICHAEL**

Age: **76** Sex: **M**  
Account#: **7230586**  
Client: **DIST 15 MEDICAL EXAMINER**

## TOXICOLOGY

Specimen Collected :09/14/2012

Lab Order No: 21171453

Reg Date: 10/23/12

Test Name	Result	Units	Cutoff/Reporting Limits
-----------	--------	-------	-------------------------

### VOLATILE PANEL - VOLP 98245

#### SPECIMEN TYPE

**ANTEMORTEM BLOOD LABELED "BERNSTEIN, SIMON L" DATED 9/12/12 1035**

ETHANOL	NONE DETECTED	g/dL	0.020
ACETONE	NONE DETECTED	mg/dL	7.5
METHANOL	NONE DETECTED	mg/dL	15.0
ISOPROPANOL	NONE DETECTED	mg/dL	15.0

#### Analysis by Gas Chromatography (GC) Headspace Injection

### BLOOD DRUG SCREEN - BDSME 98216

#### SPECIMEN TYPE

**ANTEMORTEM PLASMA LABELED "BERNSTEIN, SIMON L" DATED 9/12/12 @ 1035**

GC/MS

**Quantity Not Sufficient**

LC/MS/MS

**HYDROCODONE, ZOLPIDEM, ACETAMINOPHEN, CAFFEINE, CAFFEINE METABOLITE**

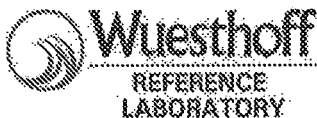### BLOOD IMMUNOASSAY SCREEN

#### SPECIMEN TYPE

**ANTEMORTEM BLOOD LABELED "BERNSTEIN, SIMON L" DATED 9/12/12 @ 1035**

AMPHETAMINES	NEGATIVE	mg/L	0.100
BARBITURATES	NEGATIVE	mg/L	0.100
BENZODIAZEPINES	NEGATIVE	mg/L	0.050
BUPRENORPHINE	NEGATIVE	mg/L	0.001
CANNABINOIDS	NEGATIVE	mg/L	0.050
COCAINE METABOLITE	NEGATIVE	mg/L	0.100
FENTANYL	NEGATIVE	mg/L	0.001
METHADONE	NEGATIVE	mg/L	0.050
OPIATES	<b>POSITIVE</b>	mg/L	0.050
SALICYLATES	NEGATIVE	mg/L	50.0





# Wuesthoff Reference Laboratory

6800 Spyglass Court  
Melbourne, Florida 32940  
Julie Bell, M.D., Laboratory Director

Patient: BERNSTEIN, SIMON  
Client Patient ID: 15-12-913  
Physician: BELL, MICHAEL

Age: 76 Sex: M  
Account#: 7230586  
Client: DIST 15 MEDICAL EXAMINER

## TOXICOLOGY

Specimen Collected :09/14/2012

Lab Order No: 21171453

Reg Date: 10/23/12

Test Name	Result	Units	Cutoff/Reporting Limits
-----------	--------	-------	-------------------------

TRICYCLICS	NEGATIVE	mg/L	0.100
------------	----------	------	-------

### ACETAMINOPHEN - ACMP 98203

#### SPECIMEN TYPE

ANTEMORTEM PLASMA LABELED "BERNSTEIN, SIMON L" DATED 9/12/12 @ 1035

ACETAMINOPHEN	16.3	mg/L	10
---------------	------	------	----

Therapeutic range:  
10.0 - 20.0 mg/L

Analysis by Enzyme Immunoassay.

### FREE OPIATES PANEL - OPPF 98182

#### SPECIMEN TYPE

ANTEMORTEM BLOOD LABELED "BERNSTEIN, SIMON L" DATED 9/12/12 @ 1035

CODEINE	NONE DETECTED	mg/L	0.025
MORPHINE	NONE DETECTED	mg/L	0.025
HYDROCODONE	0.094	mg/L	0.025
6-MONOACETYLMORPHINE	NONE DETECTED	mg/L	0.005
HYDROMORPHONE	NONE DETECTED	mg/L	0.025
OXYCODONE	NONE DETECTED	mg/L	0.025
OXYMORPHONE	NONE DETECTED	mg/L	0.025

Analysis by GC/MS

### ZOLPIDEM - ZONMS 98621

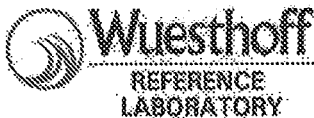#### SPECIMEN TYPE

ANTEMORTEM PLASMA LABELED "BERNSTEIN, SIMON L" DATED 9/12/12 @ 1035

ZOLPIDEM	NONE DETECTED	ng/mL	4.0
----------	---------------	-------	-----

Plasma concentrations following single oral 5 mg and 10 mg immediate release doses range from 29 - 110 ng/mL (mean, 59 ng/mL) and 58 - 270 ng/mL (mean, 120 ng/mL), respectively, occurring at a mean time of 1.6 hours. Peak plasma concentrations following a single oral 12.5 mg extended release dose ranged from 69 - 190 ng/mL (mean = 130 ng/mL) occurring at a mean time of 1.5 hrs.

The ratio of whole blood concentration to serum or plasma concentration in unknown for this analyte.



# Wuesthoff Reference Laboratory

6800 Spyglass Court  
Melbourne, Florida 32940  
Julie Bell, M.D., Laboratory Director

Patient: BERNSTEIN, SIMON  
Client Patient ID: 15-12-913  
Physician: BELL, MICHAEL

Age: 76 Sex: M  
Account#: 7230586  
Client: DIST 15 MEDICAL EXAMINER

## TOXICOLOGY

Specimen Collected :09/14/2012

Lab Order No: 21171453

Reg Date: 10/23/12

Test Name	Result	Units	Cutoff/Reporting Limits
-----------	--------	-------	-------------------------

Testing performed by NMS Labs, 3701 Welsh Rd, Willow Grove, PA 19090-2910

Specimens were intact upon receipt. Chain of custody, specimen security and integrity has been maintained. Testing has been performed as requested


Reviewed by: *Juan L. L...*

Date: 10-23-12

FINAL REPORT - THIS COMPLETES REPORTING ON THIS CASE

TOXICOLOGY\_REPORT

BERNSTEIN, SIMON



## Palm Beach County Medical Examiner's Office

Name: Simon Bernstein

Case Number: 12-0913

Prepared By: Heron Ruiz, Forensic Investigator

---

On Thursday, September 13, 2012 at about 8:15 a.m., Ted Bernstein called the Palm Beach County Medical Examiner's Office to request an autopsy on his father, Simon Bernstein, whom he said died at Delray Medical Center earlier in the morning. He said that his father is 76 years old with a history of Hepatitis, heart disease with previous open heart surgery and stents and hypertension. His father was admitted to the hospital.

I told Mr. Bernstein that the Medical Examiner would not assume jurisdiction of this case because the death did not appear to be due to anything other than natural causes. He then said that he was requesting an autopsy because after talking to his father's personal assistant, he believed that his father's younger girlfriend may have overdosed his father.

I told Mr. Bernstein to contact the appropriate law enforcement agency and to report the case.

At 9:00 a.m., Sergeant Matthew Castelli (ID: 6382) of the Palm Beach County Sheriff's Office called the Palm Beach County Medical Examiner's Office to report the case. He said that he contacted the Palm Beach County Sheriff's Office Violent Crimes Division (VCD) and that they declined to assign a Detective to this case. He said that Deputy Vince Haugh would complete a report. I told him to fax a copy of the report to the Palm Beach County Medical Examiner's Office. I told him also to have the hospital fax Mr. Bernstein's medical records to the Palm Beach County Medical Examiner's Office for review and to have the body placed in the hospital morgue.

I received the medical records from the hospital. The records state that on September 12, 2012, shortly after 10:00 a.m., Mr. Bernstein arrived at the hospital Emergency Room. He was alert and able to communicate. He reported that he suffered from fibromyalgia being treated with Prednisone. He complained of generalized weakness and dizziness since September 7, 2012. His family said that he was disoriented and that he collapsed while trying to get up. The hospital staff diagnosed him with a Myocardial Infarction and congestive heart failure.

I discussed the case with Chief Medical Examiner, Dr. Michael Bell. He told me that have the body transported to the Palm Beach County Medical Examiner's Office for further review. I contacted Mr. Bernstein and told him that the medical examiner would do an autopsy on his father's body. I instructed him to arrange services with a funeral for release of the body.

I dispatched Elite Body Removal Service to the hospital on September 14, 2012 at 8:40 a.m.

Deputy Vince Haugh sent a report to the Palm Beach County Medical Examiner. The report states that on September 13, 2012 he went to Mr. Bernstein's (decedent) home at 7020 Lions Head Lane, Boca Raton, Florida, 33496. He met with Ted Bernstein. Ted told him that his father, Simon Bernstein was taken to Delray Medical Center at about 10:00 a.m., September 12, 2012 and that he died in the early morning, September 13, 2012. He said his father's caretaker, Rachel Walker told him that his father's girlfriend, Maritz Puccio might have given his father a larger than prescribed dose of Hydrocodone and an Ambien. Ted voiced his concern at the hospital and the doctors told him that they did not suspect foul play in this case and that they would not request an autopsy.

Ms. Walker reported that the decedent suffered from Polymyalgia, Hepatitis C and had open heart surgery. The decedent recently started taking Prednisone, which affected his mental stability. She said that she found the decedent on the couch when she arrived at his home on September 12, 2012 at about 8:30 a.m. Ms. Puccio arrived home a short while later and apparently there was some disagreement on whether they should take him to the hospital. Ms. Walker ultimately decided to take him to the hospital. Ms. Walker said that the decedent received a prescription of 100 Hydrocodone pills on September 7, 2012 and that she believed that Ms. Puccio was giving him more than the prescribed doses. Ms. Walker said that she believed there were only about 30 pills left in the bottle. Deputy Haugh counted the pills and found 90.5 remaining in the bottle. He concluded that the decedent was most likely not being over medicated.

Deputy Haugh talked to Mr. Bernstein's other son, Eliot Bernstein. Eliot reported that he was out to dinner with his father and Ms. Puccio on September 8, 2012 and that his father asked Ms. Puccio for one of her Ambien's to help him sleep. Ms. Puccio refused to give him the Ambien leading to a brief argument.

Deputy Haugh collected Mr. Bernstein's medications>

1. Prednisone (5mg), 2 times daily
2. Benicar (20mg), 1 daily
3. Cartia (180mg), 2 times daily
4. Clopidogrel (75mg), 1 time daily
5. Isoborbide Mononitrate (30mg), 2 times daily
6. Pantopravole (40mg), 1 time daily
7. Ranexa (500mg), 2 times daily
8. Bayer aspirin (81mg)
9. Q-var (40mg) puff two daily
10. Serevant (1 puff), two times daily
11. Lyrica (50mg), 1 time daily
12. Vitamin D (D3), 1 daily
13. Homocysteine Formula (b625mg), folic acid

Nothing Further at this time

**From:** [Eliot Ivan Bernstein](#)  
**To:** ["Michael Bell"](#)  
**Cc:** [Caroline Prochotska Rogers Esq. \(caroline@cprogers.com\)](#); [Michele M. Mulrooney ~ Partner @ Venable LLP \(mmulrooney@Venable.com\)](#); [Andrew R. Dietz @ Rock It Cargo USA](#); [Marc R. Garber Esq. \(marcgarber@gmail.com\)](#); [Marc R. Garber Esq. @ Flaster Greenberg P.C. \(marc.garber@flastergreenberg.com\)](#); [Marc R. Garber Esq. @ Flaster Greenberg P.C. \(marcgarber@verizon.net\)](#)  
**Bcc:** [Undisclosed List: Eliot I. Bernstein, Inventor ~ Iviewit Technologies, Inc.; Patrick "Pat" Hanley \(cpsvm@yahoo.com\)](#); [Pat Handley \(svm231@aol.com\)](#); [""tourcandy@gmail.com" \(tourcandy@gmail.com\)"](#)  
**Subject:** RE: CASE NUMBER: 12-0913 --- Simon Bernstein Autopsy  
**Date:** Friday, January 10, 2014 3:45:00 PM

---

Hello Dr. Bell,

Thank you for your reply and continued efforts on my behalf and I would like to clarify a few statements in your email below. First, I did not ever tell the police I was worried about my father getting too much of his medication or that he was being poisoned. These claims came from my brother Theodore and my father's assistant Rachel Walker who believed he was murdered by his companion and so stated to the police and the hospital the day my father died on September 13, 2012. In fact, I stated that I did not believe my father was being poisoned by either over medication or other poisons by his companion Maritza Puccio as evidenced in the Police Report. I reviewed the drug toxicology you provided and agree with your assessment of that. As for what poisons may have been used when the, alleged by others, switching of pills with pills of an unknown substance took place and I agree with you that it could have been anything and which is why I requested the Police take all of his medications into evidence but they did not. I am not sure what a heavy metal screen is and what it tests for or what other poison screening tests are available, could you please clarify this for me? Further, did you review the records of my father in the 8 weeks prior to his hospitalization, which may also have significant information and may further provide evidence of possible poisoning, as he was suddenly and unexpectedly suffering during that time from a wide range of symptoms in those weeks and he was taken to several of his doctors to evaluate who were all perplexed and this led to brain scans at the hospital just days before his death. Did you get a chance to review the report on the brain scan done? I am not sure but it appears prudent in ruling out foul play that these records be reviewed from all of his doctors during that time for information that could reveal what, if any, poisons were used based on the symptoms he was suffering and the battery of tests run on him concerning all these problems. I am not represented by an attorney in this matter as there appears at this stage of inquiry no need to spend money on one and so please continue to deal directly with me as Simon's son via email or feel free to call me at my contact info below.

I pray you had a wonderful holiday season with your family and again thank you for your time, effort and consideration of these matters,

Eliot I. Bernstein  
Inventor  
Iviewit Holdings, Inc. – DL  
2753 N.W. 34th St.  
Boca Raton, Florida 33434-3459  
(561) 245.8588 (o)  
(561) 886.7628 (c)

(561) 245-8644 (f)  
[iviewit@iviewit.tv](mailto:iviewit@iviewit.tv)  
<http://www.iviewit.tv>

---

**NOTICE:** Due to Presidential Executive Orders, the National Security Agency may have read this email without warning, warrant, or notice. They may do this without any judicial or legislative oversight and it can happen to ordinary Americans like you and me. You have no recourse nor protection save to vote against any incumbent endorsing such unlawful acts.

**CONFIDENTIALITY NOTICE:**

This message and any attachments are covered by the Electronic Communications Privacy Act, 18 U.S.C. SS 2510-2521.

This e-mail message is intended only for the person or entity to which it is addressed and may contain confidential and/or privileged material. Any unauthorized review, use, disclosure or distribution is prohibited. If you are not the intended recipient, please contact the sender by reply e-mail and destroy all copies of the original message or call (561) 245-8588. If you are the intended recipient but do not wish to receive communications through this medium, please so advise the sender immediately.

\*The Electronic Communications Privacy Act, 18 U.S.C. 119 Sections 2510-2521 et seq., governs distribution of this "Message," including attachments. The originator intended this Message for the specified recipients only; it may contain the originator's confidential and proprietary information. The originator hereby notifies unintended recipients that they have received this Message in error, and strictly proscribes their Message review, dissemination, copying, and content-based actions. Recipients-in-error shall notify the originator immediately by e-mail, and delete the original message. Authorized carriers of this message shall expeditiously deliver this Message to intended recipients. See: Quon v. Arch.

\*Wireless Copyright Notice\*. Federal and State laws govern copyrights to this Message. You must have the originator's full written consent to alter, copy, or use this Message. Originator acknowledges others' copyrighted content in this Message. Otherwise, Copyright © 2011 by originator Eliot Ivan Bernstein, [iviewit@iviewit.tv](mailto:iviewit@iviewit.tv) and [www.iviewit.tv](http://www.iviewit.tv). All Rights Reserved.

---

**From:** Michael Bell [<mailto:mbell@pbccgov.org>]  
**Sent:** Friday, January 10, 2014 1:21 PM  
**To:** Eliot Ivan Bernstein  
**Subject:** RE: CASE NUMBER: 12-0913 --- Simon Bernstein

The autopsy was done at the Palm Beach ME office.

All drugs are "poisons" when given in sufficient doses. You initially told police you were worried about your father getting too much of his medications. The toxicology clearly shows that did not happen. There are thousands of drugs(poisons) and therefore it is impossible to test for all of them. If you think you know what was given, then please share that information. I will do a heavy metal screen which will take several weeks.

I have reviewed all the records of your father's hospitalization. My opinion is unchanged.

All further communication should be through your attorney who can call me at 561-688-4575.

---

**From:** Eliot Ivan Bernstein [<mailto:iviewit@iviewit.tv>]  
**Sent:** Monday, January 06, 2014 12:23 PM  
**To:** Michael Bell  
**Cc:** Caroline Prochotska Rogers Esq.; Michele M. Mulrooney ~ Partner @ Venable LLP; Andrew R. Dietz @ Rock It Cargo USA; Marc R. Garber Esq.; Marc R. Garber, Esquire @ Flaster Greenberg P.C.; Marc R. Garber Esq. @ Flaster Greenberg P.C.  
**Subject:** RE: CASE NUMBER: 12-0913 --- Simon Bernstein

Dear Dr. Bell,

I have not heard back on my email to you below. Can you please provide me a timeframe for your getting back to me? Please also include information regarding if the poison screening was done when the autopsy was conducted, not just a drug screening, as evidence exists that contact was made with the hospital on the night my father died that he may have been poisoned and similar claims were made to the Palm Beach County Sheriff the day he died. The remainder of the questions in my email still need to be addressed and as I am currently in ongoing civil and criminal complaints regarding my father, a prompt reply with an ETA would be greatly appreciated.

Thank you,  
Eliot Bernstein

---

**From:** Eliot Bernstein [<mailto:iviewit@gmail.com>]  
**Sent:** Monday, November 11, 2013 6:23 AM  
**To:** Michael D. Bell, M.D. ~ Medical Examiner @ Office of the District Medical Examiner - District 15 - State of Florida ([mbell@pbcgov.org](mailto:mbell@pbcgov.org))  
**Cc:** Caroline Prochotska Rogers Esq. ([caroline@cprogers.com](mailto:caroline@cprogers.com)); Michele M. Mulrooney ~ Partner @ Venable LLP ([mmulrooney@Venable.com](mailto:mmulrooney@Venable.com)); Andrew R. Dietz @ Rock It Cargo USA; Marc R. Garber Esq. ([marcrgarber@gmail.com](mailto:marcrgarber@gmail.com)); Marc R. Garber, Esquire @ Flaster Greenberg P.C.; Marc R. Garber Esq. @ Flaster Greenberg P.C. ([marcrgarber@verizon.net](mailto:marcrgarber@verizon.net))  
**Subject:** FW: CASE NUMBER: 12-0913 --- Simon Bernstein

Dear Dr. Bell,

Thank you for your prompt reply to my inquiry. A few more questions arose after reviewing your report. First I would like to state that there has been an arrest made in my parents' estates of the Notary Public Kimberly Moran who acted on behalf of the law firm Tescher & Spallina in forging and fraudulently creating documents for my father, after he was deceased. I have alleged to the court that these documents were part of a conspiratorial effort by primarily my brother and his friends Donald Tescher and Robert Spallina to seize control of Simon's estate post mortem and change the beneficiaries using post mortem documents. It should also be noted that in a September 13, 2013 hearing before Judge Martin H. Colin in the Del Ray Beach courthouse, it was found that the estate of my mother was closed by my father months after he was deceased, as if he were alive at the time and thus perpetrating a fraud on the court, which prompted Judge Colin to state twice that he should read Robert Spallina, Esq., Donald Tescher, Esq., Mark Manceri, Esq. and my brother Theodore Bernstein their Miranda rights for the crimes he identified at the hearing that they committed. That after Simon was deceased these fraudulent and forged documents that gave

fiduciary control to Tescher, Spallina and Ted then provided the way for far more serious felony crimes to be committed. The Palm Beach County Sheriff has made an arrest of Moran thus far and that report is filed as case # 13097087.

With that said, after reviewing your report I noted that you received my father's body, the day after he died on September 14, 2013. The reason I ask if this is correct, is that we were informed after my father died that his body had been taken to Miami to have an autopsy performed, which delayed the burial by several days as we waited for the autopsy to be performed. The autopsy was alleged by my brother, Spallina and others to be being conducted in Miami and after reviewing your report it was clear that you indicate the body never was transported to Miami. Therefore, please verify the information regarding the transportation of the body after the hospital to your offices with any/all stops in between.

I requested in my original letter to you if a poison screening had been completed, your letter stated a toxicology report was run but it appears to be a drug only test, not a poison screening. The reason this is now important is that immediately following my father's death as noted in your report materials, a claim was made to Palm Beach County Sheriff by Rachel Walker and Theodore Bernstein primarily that my father was murdered by his girlfriend, Maritza Puccio, via either overdosing or poisoning. Walker claimed that Maritza was switching pills in containers and may have been switching the pills with other substances and other substances may have been given to him, which may have included poisons or other drugs. I also note that after the officer interviewing Walker counted out the pills he was on and everything seemed in order, Walker claimed that the pain medication was not the only drug that may have been tampered with and that other substances may have been given to Simon in the weeks leading up to his death.

I do not doubt your conclusion that my father died of a heart attack but there can be many substances, including poisons that can induce a heart failure, I am trying to assess if the poison screening might have unearthed any substances in addition to the drug screen run by your agency. I am confused by some of your claims as to what occurred at the hospital that day as they contradict in part what we were told by the doctors who handled my father that day, including the following;

1. You claimed that evidence of a heart attack was found in the reports on admission to the hospital but that turned out to be wholly disproved by the end of the day.
2. Initially in the morning when we first took my father into the hospital, the first doctor attending him thought he was having a heart attack due to his prior history, despite my father claiming that he was not having a heart attack and that he knew what a heart attack felt like and he was not having one and thought he was fine, stating he was just confused and in pain from other ailments he was having.
3. Later in the afternoon the initial doctor claimed that he did not find any signs of a heart attack after running a battery of tests and called in an infectious disease doctor to evaluate and run tests, as he thought something else was going on other than heart related as he was having several other readings regarding other major organs that were highly abnormal.
4. We were assured by the cardiologist in charge of my father's care in the evening, before he let us go home that Simon's heart was fine and that NO markers were found indicating a heart attack. Instead he claimed he had "West Nile Virus" or some other virus of an unknown origin or that something else was wrong entirely, as many of his other levels he tested were off the charts, indicating something else was going on. He stated Simon would be fine, he was stable and they would begin testing in the morning.



5. We were called back to the hospital several hours later early the next morning. When I arrived my father's girlfriend Maritza had been ejected from the ICU where she was staying with Simon overnight as someone had informed the hospital that Simon might be poisoned and they had shut his room off visitors until security could arrive. When I arrived at ICU they would not at first let me in until security could escort me to my father where he was being resuscitated for a second time.

Finally, my father began developing a series of ailments several weeks prior to his death that had me and others running him to a variety of doctors to be tested for a variety of ailments, including a brain scan a few weeks prior to his death. That brain scan was run by the same cardiologist who treated my dad at the hospital the day he died and his symptoms prior to that day included strange screaming pains in his head, delusions, hallucinations and more. I wondered if you had reviewed any of his prior doctor reports in the two months leading up to his death, as we never determined the exact cause of what was making him melt down over the last weeks of life in such bizarre fashion. In fact, the cardiologist at the hospital the day he died was confused how his charts appeared fine when he did the brain scan only a few days earlier and stated he could not believe it was the same man when he got the reports at the hospital that day. Did you get a chance to review all the reports from the hospital that day and all the test results run or did you just review the admission report? If you reviewed all of the records and reports what were the other problems and tests run and what were the results. These results were of concern to the doctors that day and I wonder if any of those other problems could come from poisoning. If you ran a poison screening please provide me with the results as you did with the drug toxicology. Please feel to write back to me as I do not answer my phone much and am far easier to reach via email. I look forward to hearing from you soon. Thank you again in advance for your continued time, effort and consideration of these matters. Eliot

---

**From:** Michael Bell <[mbell@pbcgov.org](mailto:mbell@pbcgov.org)>  
**Date:** November 7, 2013 at 11:17:02 AM EST  
**To:** Eliot Ivan Bernstein <[iviewit@iviewit.tv](mailto:iviewit@iviewit.tv)>  
**Cc:** "Caroline Prochotska Rogers Esq." <[caroline@cprogers.com](mailto:caroline@cprogers.com)>  
**Subject: RE: CASE NUMBER: 12-0913 --- Simon Bernstein**

Hi Mr Bernstein,

I tried to call your cell phone, but it would not accept anymore messages because it was full.

Your father died of a heart attack that was evident at autopsy and in the hospital records (he had elevated cardiac enzymes on admission).

He did NOT have West Nile virus. This disease causes a meningoencephalitis. This was NOT present at autopsy. I have attached the additional microscopic examination report as I did not see it in the pdf you sent me.

We did a toxicology screen which showed therapeutic concentrations of acetaminophen and hydrocodone. Zolpiden was detected but the level was too low to be measured. The toxicology testing can detect hundreds of different drugs.

If you have any other questions, please call me at 561-688-4575.

---

**From:** Eliot Ivan Bernstein [<mailto:iviewit@iviewit.tv>]  
**Sent:** Saturday, November 02, 2013 7:02 PM  
**To:** Michael Bell  
**Cc:** Caroline Prochotska Rogers Esq.  
**Subject:** CASE NUMBER: 12-0913 --- Simon Bernstein

Dear Dr. Bell,

I write to you after review of your attached autopsy report on my father that raises some questions regarding the cause of death that I hope you can help answer. On September 12, 2013 when we brought my father into the hospital the first diagnoses we received in the morning was that he had a mild heart attack. After testing an infectious disease doctor was brought in who claimed it could be instead some sort of virus as it was not looking like a heart attack. Later that evening while in intensive care, a doctor came and told my family that he did not have a heart attack and that his heart was fine and instead they thought my dad had West Nile Virus or some other exotic virus and that we could go home. The doctor claimed he was stable, we could go home and they would begin testing the next day. In fact, the doctor asked me if it was I who brought my father in for a brain procedure several weeks earlier and stated that when he reviewed the file to compare to his earlier records he was stunned to see the results and stated that Simon had perfect test results just days earlier for the brain procedure and now he was off the chart on several levels. The doctor stated his problems definitely were not due to his heart as he found no markers of heart attack or other heart complications. Several hours later, I was called to the emergency room where they were attempting to resuscitate my dad but to no avail and he passed.

I was informed when he passed that they were going to do a test for West Nile Virus and other similar infectious diseases and I was wondering if these tests were also performed post mortem to rule all those causes out. Finally, I was wondering if a poison screening had been done and if one can now be done if requested.

Thank you for your time, effort and consideration in the handling of this matter.

Eliot I. Bernstein  
Inventor  
Iviewit Holdings, Inc. – DL  
2753 N.W. 34th St.  
Boca Raton, Florida 33434-3459  
(561) 245.8588 (o)  
(561) 886.7628 (c)

(561) 245-8644 (f)  
[iviewit@iviewit.tv](mailto:iviewit@iviewit.tv)  
<http://www.iviewit.tv>

---

**NOTICE:** Due to Presidential Executive Orders, the National Security Agency may have read this email without warning, warrant, or notice. They may do this without any judicial or legislative oversight and it can happen to ordinary Americans like you and me. You have no recourse nor protection save to vote against any incumbent endorsing such unlawful acts.

**CONFIDENTIALITY NOTICE:**

This message and any attachments are covered by the Electronic Communications Privacy Act, 18 U.S.C. SS 2510-2521.

This e-mail message is intended only for the person or entity to which it is addressed and may contain confidential and/or privileged material. Any unauthorized review, use, disclosure or distribution is prohibited. If you are not the intended recipient, please contact the sender by reply e-mail and destroy all copies of the original message or call (561) 245-8588. If you are the intended recipient but do not wish to receive communications through this medium, please so advise the sender immediately.

\*The Electronic Communications Privacy Act, 18 U.S.C. 119 Sections 2510-2521 et seq., governs distribution of this "Message," including attachments. The originator intended this Message for the specified recipients only; it may contain the originator's confidential and proprietary information. The originator hereby notifies unintended recipients that they have received this Message in error, and strictly proscribes their Message review, dissemination, copying, and content-based actions. Recipients-in-error shall notify the originator immediately by e-mail, and delete the original message. Authorized carriers of this message shall expeditiously deliver this Message to intended recipients. See: Quon v. Arch.

\*Wireless Copyright Notice\*. Federal and State laws govern copyrights to this Message. You must have the originator's full written consent to alter, copy, or use this Message. Originator acknowledges others' copyrighted content in this Message. Otherwise, Copyright © 2011 by originator Eliot Ivan Bernstein, [iviewit@iviewit.tv](mailto:iviewit@iviewit.tv) and [www.iviewit.tv](http://www.iviewit.tv). All Rights Reserved.

---

Under Florida law, e-mail addresses are public records. If you do not want your e-mail address released in response to a public records request, do not send electronic mail to this entity. Instead, contact this office by phone or in writing.

## Eliot Ivan Bernstein

---

**From:** Ted Bernstein <tbernstein@lifeinsuranceconcepts.com>  
**Sent:** Friday, November 30, 2012 5:46 PM  
**To:** 'Eliot Ivan Bernstein'  
**Subject:** RE: Dad Info re Autopsy and Boca PD Murder investigation

Eliot,

I don't know much about this, have been pretty much leaving this to the others.

Also, would you like to have lunch with me and Spallina one day? On the things I am working on, I can catch you up and he may be able to do same with the things in his domain. Let me know if you would and I will call him to see when he would be available.

Other than that, hope all is well and maybe we'll schedule meeting at the house around that meeting. If not, we can meet over there one day next week or the week after.

Take care...

---

**From:** Eliot Ivan Bernstein [mailto:iviewit@iviewit.tv]  
**Sent:** Thursday, November 29, 2012 10:35 PM  
**To:** Ted Bernstein; Ted Bernstein; Pamela Beth Simon; Lisa S. Friedstein; Lisa Friedstein; Jill M. Iantoni; Jill M. Iantoni; Pamela Beth Simon; candyb@rockitcargo.com  
**Subject:** Dad Info re Autopsy and Boca PD Murder investigation

Hello all,

Do we have information regarding the autopsy and police investigation into the possibilities that dad was murdered or exact cause of death? Please send me all information regarding the ongoing PD and Coroner cases, including case numbers, points of contact, pd reports and statements, including those taken from the day after he died, any conclusive reports or letters and any other information we have regarding these matters. Do we have complete hospital records and doctors' records and is anyone working on those as part of these investigations? I know some stuff has been learned since we spoke to Boca PD the day after, has anyone transmitted that information to the PD or coroner? Thanks and hope everyone had a great holiday! eb



 **VIEW**  **IT TECHNOLOGIES, INC.**  
**Surf with Vision**